

# Use of Vascade Vascular Closure System for Venous Hemostasis

Arun Nagabandi, MBBS; Supawat Ratanapo, MD; Loren Garrison Morgan, MD; Deepak Kapoor, MD

**ABSTRACT:** Access-site complications remain the most common complication from cardiac catheterization procedures, with reported incidence of 2%-3% in the current era. With the growing number of patients on chronic anticoagulation and antiplatelet medications who require venous access for cardiac procedures, we proposed that vascular closure devices (selected for characteristics optimal for venous closure) could deliver a safe and effective way to achieve rapid hemostasis, while also allowing for earlier ambulation times and shorter stays.

VASCULAR DISEASE MANAGEMENT 2017;14(8):E171-E173.

**Key words:** vascular closure device, hemostasis

Access-site complications remain the most common complication from cardiac catheterization procedures, with reported incidence of 2%-3% in the current era.<sup>1</sup> Moreover, the volume of cardiac catheterization procedures has been on the rise. Most centers are now focusing on post-procedure same-day discharges in the setting of elective outpatient procedures, as patients are placing a priority on early ambulation and early discharge. In this context, the use of vascular closure devices (VCDs) to achieve hemostasis has become more prevalent in an attempt to decrease the aforementioned complications and provide shorter recovery times and subsequently, shorter hospital length of stays. While there is a large volume of information on closure of arterial access with these devices, many centers still rely on standard manual compression for hemostasis of venous access sites due to lack of information on venous VCD use. With the growing number of patients on chronic anticoagulation and antiplatelet medications that require venous access for cardiac procedures, we propose that VCDs (selected for characteristics optimal for venous closure) could deliver a safe and effective way to achieve rapid hemostasis, while also allowing for earlier ambulation times and shorter stays.

## METHODS

We report a case series of 20 patients in whom we elected to use VCDs for femoral vein hemostasis. Most common reasons for using VCDs in our patients were being on therapeutic anticoagulation, pain and discomfort in the groin, inability to lay still for the period of bedrest per postprocedure protocol, and patient preference for early ambulation. We chose to use the Vascade vascular closure system (Cardiva Medical, Inc), which is easy to use through the existing sheath and utilizes a completely bioabsorbable extravascular collagen patch, leaving no permanent components behind.

Our institution's postprocedure protocol is 2 hours of bedrest followed by sitting up and ambulation if tolerated with no bleeding

concerns at the access site when a VCD is used. When manual compression alone is used for hemostasis after sheath removal, our protocol is 4 hours of bedrest before ambulation.

## OBJECTIVES

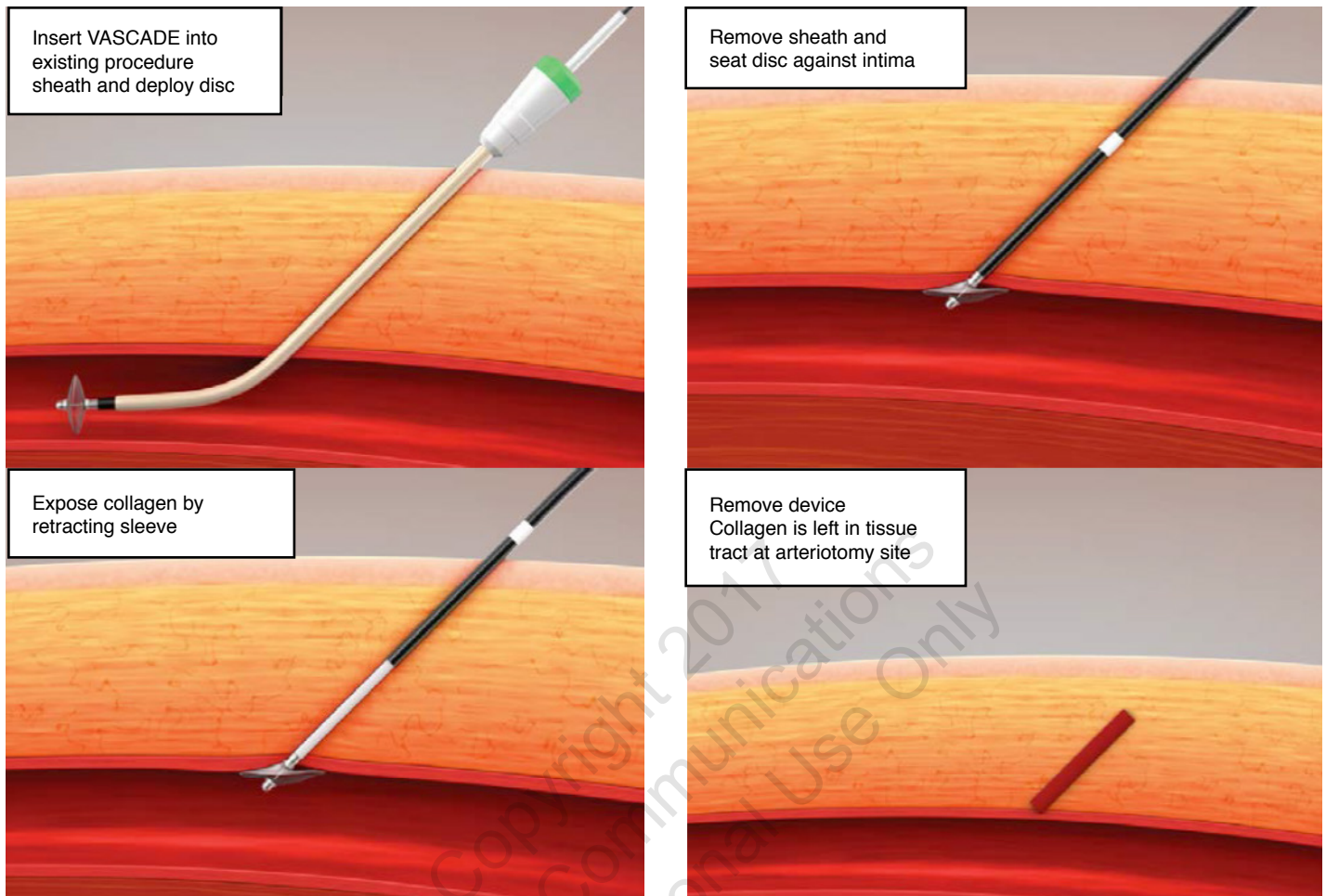
Patients were examined immediately after the procedure, after the period of bedrest, and immediately prior to discharge (3-4 hours after the procedure) on the same day and next morning when they stayed overnight. No hematomas, significant drops in hemoglobin requiring blood transfusion, access-site infections, or other complications occurred in our patient population.

## DISCUSSION

With the increasing burden of cardiovascular and pulmonary diseases, short-stay/outpatient procedures requiring femoral venous access, such as inferior vena cava filter placement, right heart catheterizations, endomyocardial biopsies, and ablation of various arrhythmias, have been steadily increasing.

Arterial access sites are more likely to be associated with local complications like hematoma and pseudoaneurysm than those on the venous side. Venous access sites are often perceived as benign due to being in a low-pressure system, but they are not immune from complications, especially when not appropriately monitored. Incomplete femoral vein hemostasis and ongoing venous bleeds are not apparent immediately after sheath removal or release of manual compression, as they can bleed very slowly over a period of hours into the subcutaneous tissue of the thigh. Consequently, complications are often discovered late in their clinical course, resulting in very large hematomas, significant pain, drop in hemoglobin (sometimes requiring blood transfusion), and hospital admission, which prolongs the length of stay.

Various VCDs are currently available on the market that are exclusively used for arterial-site hemostasis. The use of VCDs for



**Figure 1.** Vascade deployment.

venous access-site hemostasis has not been well studied aside from a few isolated and anecdotal case reports. One study, published in February 2015, assessed safety and efficacy of the Mynxgrip extravascular polyethylene glycol plug (Cardinal Health) in achieving venous hemostasis in a porcine model and concluded it was safe in achieving effective venous closure and preserved long-term vessel patency without venous thromboembolism.<sup>2</sup>

There are certain limitations to using VCDs for venous closure. Structurally, veins differ from arteries significantly in that the smooth muscle in the tunica media of veins is considerably less dense, and the outer tunica adventitia is thinner. This arrangement provides veins with improved compliance when compared with arteries, but also results in a wall that is structurally weaker, with a less effective recoil mechanism. The low flow/pressure of the venous circulation (which increases the likelihood of thrombosis if exposed to foreign materials) makes extravascular VCDs more suitable for venous closure than devices that utilize intravascular components. For example, StarClose SE VCD (Abbott Vascular), which uses a nitinol clip, and AngioSeal VCD (Terumo), which uses a small intravascular anchor in conjunction with extravascular collagen plug, are less suitable for venous closure. This is due to lack of venous wall thickness, which is needed to grasp and

cinch together when deploying the StarClose device, and the thrombogenicity of the retained footplate in the area of slow flow of the femoral vein, which can predispose to deep venous thrombosis formation. In our experience, the Mynxgrip is suitable for venous closure because it is a completely extravascular polyethylene-glycol plug-based device, but the small balloon used to anchor against the vessel wall has been known to sometimes slip through the access site when used in veins, due to the tapered nature of the balloon surface and the structurally weaker vessel wall. The subcutaneous “figure-of-eight” stitch can be utilized as well, but it is more time consuming and has a steeper learning curve. In our institution’s experience, we have tried several methods for venous hemostasis over the past decade, and nothing has consistently been as effective and easy to use as the Vascade VCD.

Vascade is a completely extravascular bioabsorbable collagen-patch based system for femoral access closure. It uses a collapsible nitinol disc that provides a large non-tapering anchor within the vessel, which prevents it from slipping through the venous access site, allowing the enclosed collagen patch to be deployed on the extravascular surface of the vein (Figure 1). It is easily introduced through the existing access sheath, minimizing blood loss, and is

very intuitive, with a short learning curve. In the randomized controlled RESPECT trial,<sup>3</sup> Vascade was shown to significantly decrease time to hemostasis, time to ambulation, time to discharge eligibility, and minor complication rate when compared with manual compression, proving its safety and efficacy.

## CONCLUSION

In our institution's experience with this small case series, under very experienced operators' supervision, the Vascade vascular closure system can be safely and effectively used for venous access-site hemostasis. This device achieved complete hemostasis without any recorded vascular complications and was effective in providing earlier ambulation and discharge compared with our standard protocol for manual compression. ■

*From the Department of Cardiology, Augusta University, Medical College of Georgia, Augusta, Georgia.*

*Disclosure: The authors have completed and returned the ICMJE Form for Disclosure of Potential Conflicts of Interest. The authors report no financial relationships or conflicts of interest regarding the content herein.*

*Manuscript submitted April 10, 2017, provisional acceptance given May 7, 2017, final version accepted May 26, 2017.*

*Address for correspondence: Deepak Kapoor, MD, Department of Cardiology, Augusta University, Medical College of Georgia. Email: dkapoor@augusta.edu*

## REFERENCES

1. Chandrasekar B, Doucet S, Bilodeau L, et al. Complications of cardiac catheterization in the current era: a single-center experience. *Catheter Cardiovasc Interv*. 2001;52:289-295.
2. Srivatsa SS, Srivatsa A, Spangler TA. Mynx vascular closure device achieves reliable closure and hemostasis of percutaneous transfemoral venous access in a porcine vascular model. *J Invasive Cardiol*. 2015;27:121-127.
3. Hermiller JB, Leimbach W, Gammon R, et al. A prospective, randomized, pivotal trial of a novel extravascular collagen-based closure device compared to manual compression in diagnostic and interventional patients. *J Invasive Cardiol*. 2015;27:129-136.

Copyright 2017  
HMP Communications  
For Personal Use Only